



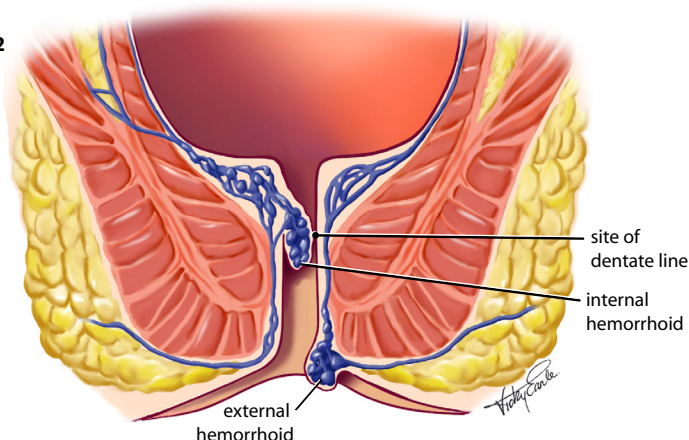
What are Internal Hemorrhoids?

Hemorrhoids are engorged vessels in and around the back passage. Anatomically some say they are similar to varicose veins in the leg. In fact they are enlargement of the three cushions of vascular tissue above the dentate line which join the intra-abdominal veins to the veins outside the anus. Also the three cushions are in proximity to the terminal three branches of the inferior mesenteric artery –the left, right anterior and right posterior rectal arteries. The veins must join with small arteries because the complaint of sufferers is that the blood is bright red when they bleed. Studies by Thulesius and Gjores² determined partial pressures of oxygen at 95.6mm Hg and percentages of oxygen saturation in the hemorrhoidal blood at 97.4% - close to the values in arterial blood measured simultaneously at 98mm and 97% respectively. They lie in the left lateral, right posterior and right anterior positions and can be shrunk by interrupting the vein clusters about 1 centimeter above the dentate line in the anus where there are no pain nerves.

Definitions

Internal hemorrhoid: a dilated varicose group of vessels arising from the junction between the internal and mid hemorrhoidal plexus located above the dentate line and covered by columnar mucosa (figure 2). The hemorrhoids are classified according to degree of prolapse (Banov¹) :

Fig.2



Grade 1: There is a tuft of internal hemorrhoidal tissue but no prolapse from the anal canal. These produce painless bleeding.

Grade 2: These bleed but also prolapse from the anal canal when the patient strains. They retract after the bowel movement and often the patient does not even know they are prolapsing. They may be demonstrated by watching the patient in the act of straining or identified on anoscopic examination by grasping the hemorrhoid with a forceps and gently pulling it externally.

Grade 3: These are easily identified because they prolapse with a bowel movement and remain out. The patient has to replace them manually. Grade 3 hemorrhoids may be associated with bleeding and perhaps with an aching pain.

Grade 4: These remain prolapsed externally all the time and won't stay reduced. There



is often a mucoid discharge from the hemorrhoids along with bleeding, and the surface may undergo metaplasia which is evidence of chronic external exposure. In each of these cases the external hemorrhoidal component may be simultaneously involved. The external hemorrhoids may swell and become painful from inflammation and/or thrombosis.

External hemorrhoids: these can be confused with prolapsed internal hemorrhoids but strictly speaking an external hemorrhoid is a hemorrhoid in the external hemorrhoidal plexus. These can develop clot(s) in them about the size of a pea.

Causes: The cause of hemorrhoids is anything that increases intra-abdominal pressure over time such as constipation or diarrhea or obesity or heavy lifting. Pregnancy is a good example of a short period of increased pressure, relieved when the baby is delivered and this type of hemorrhoid may not require any major treatment. Lack of soluble fiber (e.g. bran) and insufficient water and straining for a long time on the toilet are major factors in causing hemorrhoids and fissures and their complications.

Travel: It is important to recognize that airline travel and pressurized aircraft can give problems with upset bowels and hemorrhoid exacerbations. The best advice is to pack a whole-wheat sandwich to eat,

avoid food and alcohol on the plane, drink as much water as you can from the service and supplement this with two liters of water you take on board the plane. Try to walk about as much as you can on the flight.

Natural history: Hemorrhoids get larger with time and may bleed or itch at the beginning but later come out transiently or even stay out all the time. Tags can form on the outside and sometimes the hemorrhoids can thrombose and become very painful. When there are large tags it may be difficult to keep the area clean and there may be a discharge and itch or irritation. After the age of 50 years 50% of people will have hemorrhoids but only 1% will need treatment each year. 97% are treated with banding.

Methods of treatment: The best treatment is prevention by taking enough dietary fiber (2 tablespoons of bran or Metamucil® or Citrucel® or psyllium or Benefiber®) and 7 to 8 glasses of water per day and not being overweight and taking some exercise. With the development of early hemorrhoids this is usually still the best way to manage the problem and the addition of a cream (no difference between most of the emollient creams, so go cheap) is usually sufficient. The use of a steroid cream or analgesic ointment should generally not be used for longer than a week. Suppositories are helpful. An important change that will help is not spending longer than 2 minutes on the toilet to have a bowel movement, and going



back a few hours later if you cannot have a bowel movement then. If this does not work, you will likely be sent to a specialist who will first of all make sure that hemorrhoids are the only problem. If there is a family history of cancer, or if there is weight loss or blood mixed in with the stool or a lot of pain, other causes such as inflammatory bowel disease, fissure or even bowel cancer will need to be ruled out. Usually you will have a digital rectal exam and proctoscopy but a sigmoidoscopy or colonoscopy may be needed depending on the risk factors. Although laser, injection of sclerosant, or infrared are used for a few patients the vast majority of hemorrhoids are treated by rubber band ligation since the 1960's. A few patients with advanced hemorrhoids (Grade 4) may require surgery because of the large amount of hemorrhoid protruding through the anus, but it is still often worth trying ligation because it is so much better accepted by the patient, and the external lump(s) may shrink by as much as 80%. Because of the issues related to sterilization of instruments between cases there has been a need for a disposable ligator. The advent of HIV, the recognition of the highly infectious Hepatitis B and C have made patients and health professionals switch to disposables whenever feasible for other procedures. The advent of the CRH proctoscope and bander (O'Regan) makes this important improvement available now for hemorrhoids.

Procedure: The patient is informed of the steps in the procedure, and placed on a

couch on the left side with only the anal area exposed. The surgeon is gloved. He performs a digital exam and then directs the lubricated proctoscope into the anus pointing it towards the umbilicus first and then after three centimeters, backwards and inserts the proctoscope fully and then removes the obturator. With the aid of a bright wall or floor lamp the three hemorrhoidal masses are identified and the internal foramen turned towards each in turn starting with the left, then the right anterior then the right posterior. Each of the hemorrhoids is sucked into the syringe ligator and twisted 90 degrees clockwise and 180 degrees anticlockwise (figure 4, one technique and figure 5, another technique). If this is at the right point (2 cm above the dentate line at the L angle®) the patient will have no pain and the barrel of the syringe can be locked and the band fired onto the pedicle. Otherwise, if there is discomfort, the vacuum is release and the tip of the syringe applied higher up. Usually only one band is performed at each visit as it has been shown that multiple ligations have more complications. The technique of sucking the right part of the hemorrhoid and locking the syringe requires some practice, and can be done with one hand without repositioning the fingers or with one hand locking the barrel with the thumb and repositioning the fingers for the final locking movement. There is a feeling of fullness and slight discomfort but pain is rare. If pain occurs it comes on immediately and can be quickly relieved on the spot by moving the band a little with a gloved finger.



The hemorrhoids can be done one at a time and repeated in the order noted at weekly intervals until all three are done. Following the procedure the patient should take a high fiber diet and 7 to 8 glasses of water to avoid constipation. Painkillers such as plain Tylenol® or local anesthetic cream such as EMLA® is all that is required. The patient may feel a fullness of the rectal area for up to 24 hours. Complications are extremely rare (less than 0.3% procedures) and include bleeding, difficulty in passing urine and – more rarely still – bacteremia (none so far). The patient should be seen and re-examined in two weeks.

Fig. 4

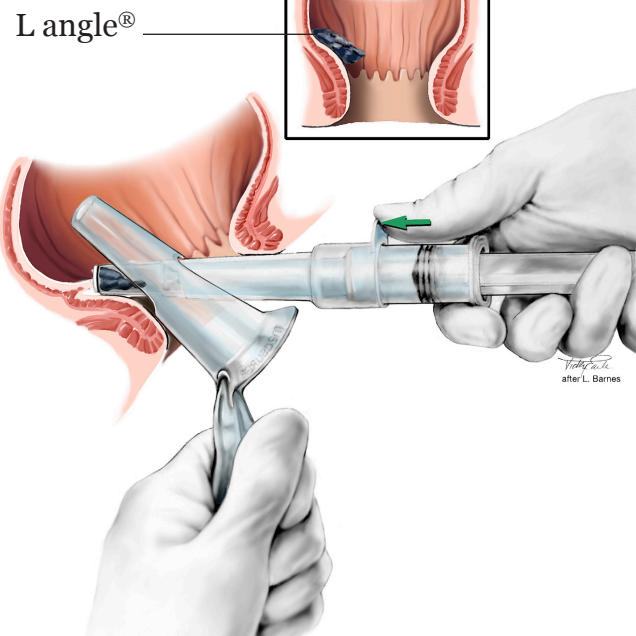
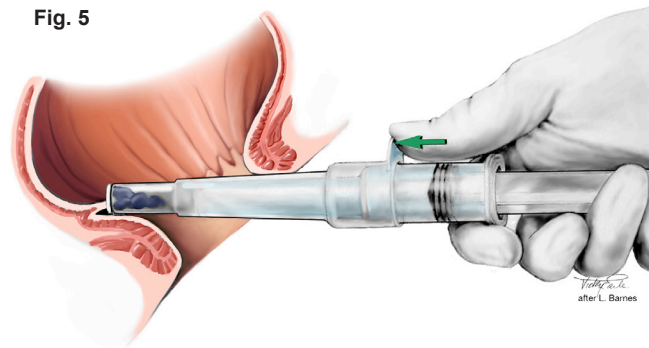


Fig. 5



References

1. Banov L Jr, Knoepp LF Jr, Erdman LH, Alia RT. Management of hemorrhoidal disease. J S C Med Assoc 1985;81:398-401.
2. Thulesius, O. and Gjores, JE Arterio-Venous Anastomosis in the Anal Region with Reference to the Pathogenesis and Treatment of Haemorrhoids. Acta Chirurgica Scandinavica, 139:476-478, 1973.