



## Method of Treatment of Hemorrhoids

The anoscope is inserted and the handle turned to the hemorrhoid to be banded and the obturator withdrawn and the hemorrhoid appears in the cut out. The CRH bander is inserted and suction applied to the apex of the hemorrhoid at the L angle<sup>®</sup> 2 cm above the dentate line, and the plunger withdrawn and the bander rotated 90 degrees clockwise and and the same anticlockwise. Then wait for up to 20 seconds. If there is no pain the band is fired and the instruments withdrawn and the position of the band checked by rectal to make sure there is no muscle wall picked up (the cause of all the problems with previous banding techniques I believe). If there is any discomfort the band is rolled upwards with the finger tip until no discomfort is present. Usually the left right posterior and right anterior hemorrhoids are banded in successive 10 days periods. If the blind technique is used (preferable if there is a fissure) the instrument is inserted until the skin of the anus is between the two lines on the proctoscope, the instrument angled to hit the spot 2 cm above the dentate line in the desired left or other location, the plunger withdrawn and locked, the band fired and the rectal exam as before (figures 4 and 5).

Fig. 4

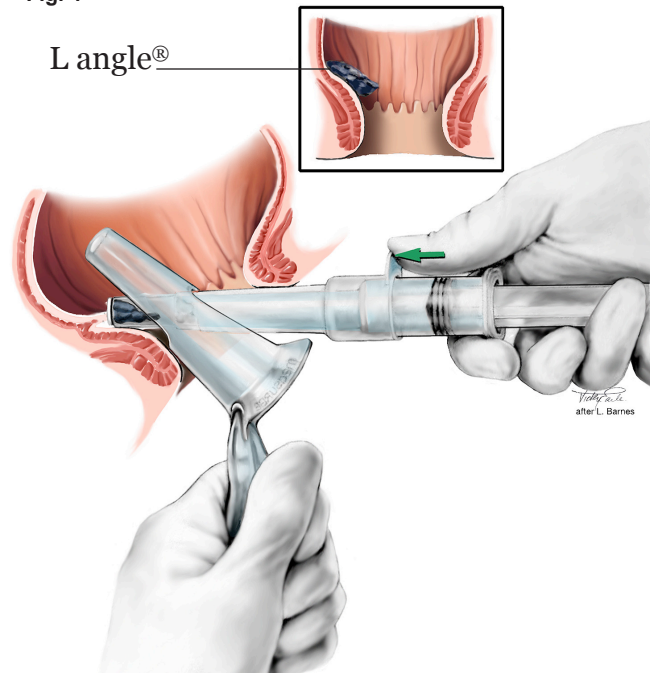


Fig. 5

